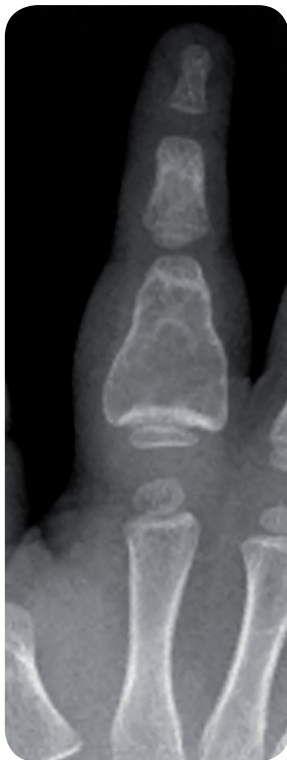

BonAlive[®] granules for filling an ABC bone tumour cavity in a child

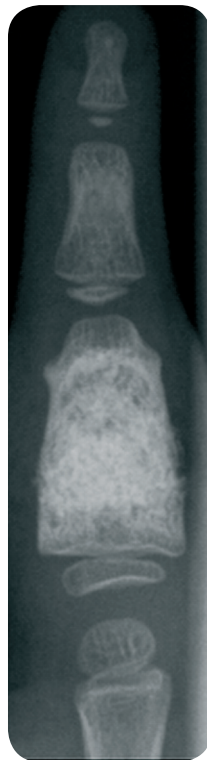
Patient history: A three-year-old boy was diagnosed with a recurrent aneurysmatic bone cyst (ABC) in the proximal phalanx of the finger.

Operation: The tumor was evacuated and the cavity was filled with BonAlive[®] granules (2 cc; 0.5-0.8 mm mixed with a small amount of autologous bone). The operation was performed at the Helsinki University Hospital, Finland in 2007.

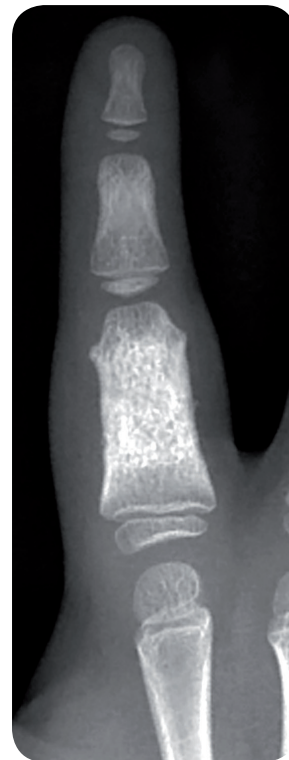Follow-up: During the two-year follow-up, the filled cavity appeared dense on X-ray and no sign of a recurrent cyst was observed. The phalanx had grown in length and remodeled to an almost normal shape.



Pre-op



Post-op 12 months



Post-op 24 months

Source: Lindfors, Nina C., Treatment of a recurrent aneurysmal bone cyst with bioactive glass in a child allows for good bone remodelling and growth, Bone, 2009, 45(2)398-400.

Photos © Helsinki University Hospital, Finland